

Anaerobic bacterial pericardial effusion in a cat

R G Lobetti^a

ABSTRACT

A 9-year-old male cat was presented for evaluation of chronic weight loss and was subsequently diagnosed with pericardial effusion. The effusion was quantified as a septic exudate caused by the anaerobic bacterium *Peptostreptococcus*. Antibiotic therapy resulted in complete resolution of the pericardial effusion. As *Peptostreptococcus* is a common oral bacterium and the cat had a previous dental procedure, it is speculated that the pericardial effusion was secondary to bacteraemia from the dental procedure.

Key words: dental, feline, *Peptostreptococcus*, pericarditis.

Lobetti R G **Anaerobic bacterial pericardial effusion in a cat.** *Journal of the South African Veterinary Association* (2007) 78(3): 00–00 (En.). Bryanston Veterinary Hospital, PO Box 67092, Bryanston, 2021 South Africa.

INTRODUCTION

In general, pericardial diseases in small animal practice are rare, with pericardial effusion being the most commonly encountered pericardial disease². Septic pericarditis, although well recognised in cattle and humans, has rarely been reported in either the dog or cat^{5,8}. Septic pericarditis can result from pleural or pulmonary infections, secondary to trauma, or from haematogenous spread⁵. Clinical signs associated with pericarditis include weight loss, pyrexia, weakness, dyspnoea, ascites, and if extensive, cardiac tamponade⁵.

In cats an antemortem diagnosis of pericardial disease is rarely obtained¹¹. In a retrospective study, 66 cats out of 2852 (2.3 %) autopsied had pericardial disease, with pericardial effusion present in 58 and pericarditis without significant effusion in 8¹¹. The most common cause of pericardial effusion in the cat is feline infectious peritonitis^{2,11}, with other causes being neoplasia, cardiomyopathy, infections (bacterial, fungal), coagulopathies, hyperthyroidism, and left atrial tears².

This report describes a case of bacterial pericarditis in a cat caused by the anaerobic bacterium *Peptostreptococcus*.

CASE HISTORY

A 9-year-old castrated male cat was presented for evaluation of progressive weight loss with reduced activity and appetite. Four months prior to presentation the cat had been diagnosed with severe stomatitis and dental disease that had been managed by dental scaling and

extractions, which had resulted in complete resolution of the stomatitis. Three days prior to and for 10 days after the dental therapy the cat had been treated with clindamycin (Antirobe, Pfizer Laboratories, Sandton, South Africa) at 10 mg/kg twice a day.

On clinical examination, weight loss with moderate muscle atrophy, pyrexia (40.5 °C), and a small wound on the left shoulder area were present. No abnormalities were detected on thoracic auscultation. Urine and faecal analyses were both within normal limits. Marginal non-regenerative anaemia, band neutrophilia, hypoalbuminaemia, and hyperglobulinaemia were evident on haematology and serum biochemistry (Table 1). On serum protein electrophoresis the hyperglobulinaemia was quantified as marked gammaglobulinaemia and mild alpha 2-globulinaemia, indicating chronic antigenic stimulation. FIV antibody and FeLV antigen were both negative and abdominal ultrasonography was within normal limits. On a lateral survey thoracic radiograph, mild border effacement of the heart and fissure lines were evident; whereas a widened caudal mediastinum was evident on a dorso-ventral survey thoracic radiograph. Right lateral echocardiography showed the presence of anechoic fluid within the pericardial sac (Fig. 1), normal cardiac parameters, and no pleural effusion evident. The radiographic changes were ascribed to pulmonary congestion. Under ultrasound guidance approximately 20 ml of purulent fluid was aspirated from the pericardial sac. On cytology of the fluid the majority of the cells were degenerative neutrophils, few active macrophages

were present, and there were free and phagocytosed bacteria. Aerobic and fungal cultures of the fluid were both negative, whereas a pure growth of *Peptostreptococcus* was identified on anaerobic culture (Golden Vetpath Laboratories, Johannesburg, South Africa). Antimicrobials that the organism was susceptible to were penicillin, cephalosporin, quinolones, and erythromycin.

The cat was treated with 50 mg amoxicillin-clavulanic acid (Synulox, Pfizer Laboratories, Sandton) twice a day. Within 48 hours of starting the antibiotics, the pyrexia had resolved and the cat was eating. The antibiotic therapy was continued for a further 3 weeks. On re-assessment 21 days later the cat showed marked improvement in appetite and activity. Clinically the cat showed weight gain and no pyrexia. The anaemia, band neutrophilia, and hypoalbuminaemia had resolved, and the hyperglobulinaemia had improved. Survey thoracic radiographs were within normal limits and right lateral echocardiography showed resolution of the pericardial effusion (Fig. 2). Six weeks after the re-assessment, the owner reported telephonically that the cat was clinically well.

DISCUSSION

Bacterial pericarditis caused by infectious agents is uncommon in the dog and rare in the cat⁵. Septic pericarditis due to *Pasteurella* has been reported in a cat that presented with acute onset anorexia, dyspnoea, and cardiac tamponade as a result of an exudative effusion¹⁰. In a retrospective study¹¹, 3 cats were diagnosed with bacterial pericarditis; however, in all 3 cases the pericardium was not the primary site of infection. In the cat, bacterial pericarditis has been associated with pyelonephritis, pyothorax, pneumonia, and FeLV-associated disease¹¹. In the dog septic pericarditis is also rare with few reported cases in the literature^{1,7,8,13}. These cases were mostly trauma-related and secondary to intra-pericardial foreign body penetration, usually by migrating plant seeds (foxtails). It would therefore appear from the literature that bacterial pericarditis in both the dog and cat is usually secondary to debilitating systemic or pleural infections with subsequent

^aBryanston Veterinary Hospital, PO Box 67092, Bryanston, 2021 South Africa. E-mail: rlobetti@mweb.co.za

Received: April 2007. Accepted: July 2007.

pericardial involvement. Septic pericarditis can, however, also result from haematogenous spread⁵. In humans possible aetiologies for anaerobic pericarditis include: (1) spread from a contiguous focus of infection, either *de novo* or after surgery or trauma (pleuropulmonary, oesophageal fistula or perforation, and odontogenic); (2) spread from a focus of infection within the heart, most commonly from endocarditis; (3) haematogenous infection, and (4) direct inoculation as a result of a penetrating injury or cardiothoracic surgery³.

In humans purulent pericarditis is uncommon¹². Anaerobic bacterial pericarditis accounts for approximately 40 % of cases with *Prevotella*, *Peptostreptococcus*, and *Propionibacterium acnes* being the prevalent organisms isolated³. Unfortunately there is no such data available in the veterinary literature. In a review of 29 cases of anaerobic pericarditis¹², 16 cases only had anaerobic bacteria isolated, while in 13 cases anaerobes were isolated with a mixture of facultative and/or aerobic bacteria. However, anaerobic bacteria predominate in patients with pericarditis secondary to orofacial and dental infections³. In humans, infections occurring above the diaphragm are often associated with anaerobic bacteria originating from the mouth⁶ and anaerobes can be a common cause of bacterial infections of endogenous origin⁴. Anaerobes make up a significant proportion of the normal bacterial flora of the dog and cat and are predominately found on mucosal surfaces and play an important role in periodontal disease⁶. Bacteraemia is also commonly associated with localised anaerobic infections, although this is often not recognised⁶.

In humans bacteraemia with *Peptostreptococcus* is an uncommon clinical manifestation¹⁵, with obstetrical patients at greatest risk. However, anaerobic bacteraemia has been reported in 72 % of humans undergoing dental extraction with 22 % of cases associated with *Peptostreptococcus*⁹. Factors associated with an increased incidence of bacteraemia following dental extraction included presence of inflammatory dental and gum disease, age of patient, and multiple teeth extractions⁹. As these three factors were present in this cat, it is speculated that the *Peptostreptococcus* pericarditis in the cat in this report developed secondary to bacteraemia following the dental extractions. This resulted in a chronic debilitating disease that was characterised by weight loss, anaemia, and hyperglobulinaemia. The chronicity of the disease in this cat is further supported by the marked hypergammaglobulinaemia.

Table 1: Haematology and serum biochemistry results.

Parameter	Day 1	Day 21	Normal
Red cell count	7.19	9.4	5.5–10 × 10 ¹² /l
Haemoglobin	10.1	13.4	8–14 g/dl
Haematocrit	28	43	30–45 %
Mean cell volume	39	43	39–55 fl
Mean cell haemoglobin concentration	36	33	30–36 g/dl
Thrombocytes	246	229	200–600 × 10 ⁹ /l
White cell count	15.1	7.56	7–20 × 10 ⁹ /l
Neutrophils	12.99	4.08	2.5–12.5 × 10 ⁹ /l
Band cells	1.21	0.08	0–0.3 × 10 ⁹ /l
Lymphocytes	0.45	1.13	1.5–7 × 10 ⁹ /l
Monocytes	0.3	0.23	0–0.8 × 10 ⁹ /l
Eosinophils	0.15	2.04	0.1–1.5 × 10 ⁹ /l
Basophils	0	0	0–0.1 × 10 ⁹ /l
Sodium	148	ND*	143–160 mmol/l
Potassium	4.5	ND	3.6–5.1 mmol/l
Calcium	2.04	ND	2–3 mmol/l
Urea	7.5	ND	7–11 mmol/l
Creatinine	106	ND	80–140 imol/l
Total protein	82	64	54–72 g/l
Albumin	20	26	20–30 g/l
Globulins	62	38	25–38 g/l
α1 globulins	2.55	ND	3–9 g/l
α2 globulins	11.25	ND	3–9 g/l
β globulins	7.16	ND	4–9 g/l
γ globulins	40.1	ND	17–27 g/l
Glucose	5.1	ND	3.8–6.5 mmol/l
ALT	22	ND	5–30 U/l
ALP	29	ND	100–150 U/l
GGT	7	ND	7–14 U/l

*Not done.

Clinical signs associated with pericarditis include weight loss, pyrexia, weakness, dyspnoea, cardiac tamponade, and ascites⁵. Weight loss and pyrexia were present in this cat. On clinical pathology anaemia, neutrophilia, hypoalbuminaemia, and hyperglobulinaemia were present, which is similar to what has been reported in the dog¹³. These clinical and clinical-pathological abnormalities

resolved with resolution of the septic pericarditis in this cat.

Typical radiographic findings of canine pericardial effusion include an enlarged and globoid cardiac silhouette, tracheal elevation, widening of the caudal vena cava, and overlapping of the cardiac silhouette and the diaphragm¹⁴. As these findings are only present if there is a large volume of fluid in the pericardial sac, they

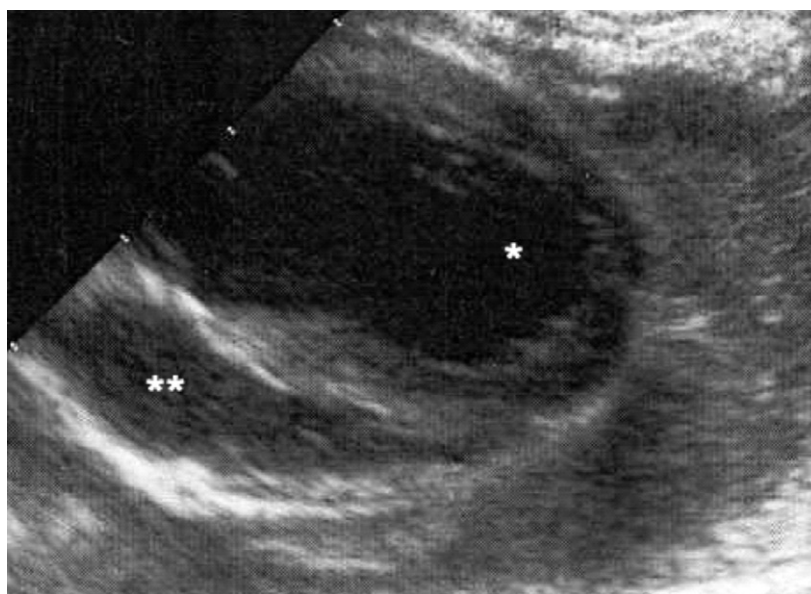


Fig. 1: Long axis right parasternal echocardiogram showing the left ventricle (*) and accumulation of anechoic fluid in the pericardial space (**).

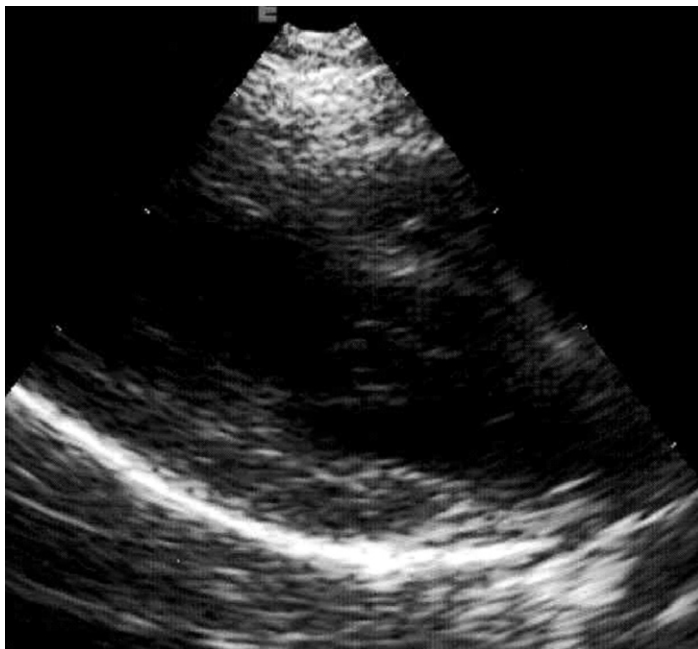


Fig. 2: Follow-up long axis right parasternal echocardiogram showing the left ventricle and atrium with resolution of the pericardial effusion.

were not that obvious in this cat. Two-dimensional echocardiography is the most sensitive and specific non-invasive method to confirm the presence of pericardial effusion¹⁴. With echocardiography the pericardial effusion appears as an anechoic space surrounding the heart, as was seen in the case report.

In general, therapy of infectious pericarditis requires pericardiocentesis for drainage of the purulent material and the administration of antimicrobial agents³. In dogs, combination of surgical drainage, removal of the foreign body and long-term antibiotic therapy gives a good prognosis¹. In humans the treatment of bacterial pericarditis also entails adequate drainage and appropriate antibiotic

therapy, and in all cases there should be a search for the source of the organism infecting the pericardium¹². Similarly, in this cat limited drainage and the use of antibiotics resulted in resolution of the pericardial effusion.

In conclusion, although bacterial pericarditis is rare in the cat, the condition should be suspected in a cat that develops pyrexia of unknown origin after a dental procedure.

REFERENCES

1. Aronson A R, Gregory C R 1995 Infectious pericardial effusion in five dogs. *Veterinary Surgery* 24: 402–407
2. Bouvy B M, Bjorling D E 1991 Pericardial effusion in dogs and cats. Part I. Normal pericardium and causes and patho-

physiology of pericardial effusion. *Compendium on Continuing Education for the Practicing Veterinarian* 13: 417–424

3. Brook I, Frazier E H 1996 Microbiology of acute purulent pericarditis. A 12-year experience in a military hospital. *Archives of Internal Medicine* 156: 1857–1860
4. Brook I 2002 Pericarditis due to anaerobic bacteria. *Cardiology* 97: 55–58
5. Calvert C A, Wall M 2006 Cardiovascular infections. In Greene C E (ed.) *Infectious diseases of the dog and cat* (3rd edn). Saunders Elsevier, St Louis: 841–865
6. Greene C E, Jang S 2006 Anaerobic infections. In Greene CE (ed) *Infectious diseases of the dog and cat* (3rd edn). Saunders Elsevier, St Louis: 381–388
7. Lorenzana R, Richter K, Ettinger S J, Lippincott C L, Kisseberth W C 1985 Infectious pericardial effusion in a dog. *Journal of the American Animal Hospital Association* 21: 725–728
8. Luis Fuentes V, Long K L, Darke P G 1991 Purulent pericarditis in a puppy. *Journal of Small Animal Practice* 32: 585–588
9. Okabe K, Nakagawa K, Yamamoto E 1995 Factors affecting the occurrence of bacteraemia associated with tooth extraction. *International Journal of Maxillofacial Surgery* 24: 239–242
10. Owens J M 1977 Pericardial effusion in the cat. *Veterinary Clinics of North America: Small Animal Practice* 7: 373–383
11. Rush J E, Keene B W, Fox P R 1990 Pericardial disease in the cat: a retrospective evaluation of 66 cases. *Journal of the American Animal Hospital Association* 26: 39–46
12. Skiest, D J, Steiner D, Werner M, Garner J G 1994 Anaerobic pericarditis: case report and review. *Clinical Infectious Diseases* 19: 435–440
13. Stafford Johnson J M, Martin M W S, Stidworthy M F 2003 Septic fibrinous pericarditis in a cocker spaniel. *Journal of Small Animal Practice* 44: 117–120
14. Tobias A H 2005 Pericardial disorders. In Ettinger S J, Feldman E C *Textbook of veterinary internal medicine* (6th edn). Saunders Elsevier, St Louis: 1104–1118
15. Topiel M S, Simon G L 1986 *Peptococcaceae* bacteraemia. *Diagnostic Microbiology and Infectious Diseases* 4: 109–117